

## CLINICAL INVESTIGATIONS

# Soft Tissue Alterations in Esthetic Postextraction Sites: A 3-Dimensional Analysis

V. Chappuis<sup>1\*</sup>, O. Engel<sup>1</sup>, K. Shahim<sup>2</sup>, M. Reyes<sup>2</sup>, C. Katsaros<sup>3</sup>, and D. Buser<sup>1</sup>

**Abstract:** Dimensional alterations of the facial soft and bone tissues following tooth extraction in the esthetic zone play an essential role to achieve successful outcomes in implant therapy. This prospective study is the first to investigate the interplay between the soft tissue dimensions and the underlying bone anatomy during an 8-wk healing period. The analysis is based on sequential 3-dimensional digital surface model superimpositions of the soft and bone tissues using digital impressions and cone beam computed tomography during an 8-wk healing period. Soft tissue thickness in thin and thick bone phenotypes at extraction was similar, averaging 0.7 mm and 0.8 mm, respectively. Interestingly, thin bone phenotypes revealed a 7-fold increase in soft tissue thickness after an 8-wk healing period, whereas in thick bone phenotypes, the soft tissue dimensions remained unchanged. The observed spontaneous soft tissue thickening in thin bone phenotypes resulted in a vertical soft tissue loss of only 1.6 mm, which concealed the underlying vertical bone resorption of 7.5 mm. Because of spontaneous soft tissue thickening, no significant differences were detected in the total tissue loss between thin and thick bone phenotypes at 2, 4, 6, and 8 wk. More than 51% of these dimensional alterations occurred within 2 wk of

healing. Even though the observed spontaneous soft tissue thickening in thin bone phenotypes following tooth extraction conceals the pronounced underlying bone resorption pattern by masking the true bone deficiency, spontaneous soft tissue thickening offers advantages for subsequent bone regeneration and implant therapies in sites with high esthetic demand (Clinicaltrials.gov NCT02403700).

**Key Words:** wound healing, regeneration, tooth extraction, bone remodeling, three-dimensional imaging, clinical trial.

## Introduction

Even though the facial soft tissue morphology plays a pivotal role in the achievement of esthetic success in the anterior maxilla (Belsler et al. 1998), the impact of dimensional soft tissue alterations in postextraction sites has received little attention in clinical research (Sculean et al. 2014). Wound healing is a complex process that requires spatially and temporally regulated expression as well as coordinated interplay between many different types of tissues and cells (Sato and Takeda 2007; Gurtner et al. 2008). As a consequence, wound healing of extraction sockets results not only in dimensional alterations of the underlying bone but also of the surrounding soft

tissue architecture. However, research related to dimensional alterations postextraction has mainly focused on the biology of bone (Cardaropoli et al. 2003). Knowledge of dimensional alterations of the overlying facial soft tissues and their contribution to postextraction bone modeling is scarce and poorly understood.

Pronounced morphologic and dimensional alterations have been described in particular for the facial bone wall in experimental and clinical research (Araujo and Lindhe 2005; Chappuis et al. 2013). In patients, the thickness of the facial bone wall thickness is most often below 1 mm and therefore corresponds to a thin bone wall phenotype (Januario et al. 2011). Within 8 wk of healing, these thin bone phenotypes reveal a median mid-facial vertical bone loss of 62.3% or 7.5 mm (Chappuis et al. 2013). Attempts have been made to preserve the facial bone wall by immediate implant placement (Araujo et al. 2005), by immediate socket grafting (Araujo et al. 2015), or by augmenting the facial bone plate (Favero et al. 2015). All these attempts have failed to arrest the inevitable biological process of extraction socket modeling in particular with respect to the preservation of the facial bone wall (Avila-Ortiz et al. 2014). Thus, the biological events driving healing of extraction sockets and their translation into clinical concepts in

DOI: 10.1177/0022034515592869. <sup>1</sup>Department of Oral Surgery and Stomatology, School of Dental Medicine, University of Bern, Bern, Switzerland; <sup>2</sup>Institute for Surgical Technology and Biomechanics, University of Bern, Bern, Switzerland; and <sup>3</sup>Department of Orthodontics and Dentofacial Orthopedics, School of Dental Medicine, University of Bern, Bern, Switzerland; \*corresponding author, vivianne.chappuis@zmk.unibe.ch

implant therapy are only beginning to be understood (Chen and Buser 2014).

The aim of the present clinical study was to investigate dimensional alterations of the facial soft tissue morphology in the esthetic zone of single extraction sites by sequential digitized impressions in comparison with the underlying facial bone phenotype analyzed by 2 consecutive cone beam computed tomography (CBCT) images obtained at extraction and after 8 wk. The hypothesis to be tested in this study is determine if a significant spontaneous soft tissue thickening can be observed after 8 wk of healing in thin and thick bone wall phenotypes. The primary objective was to analyze the facial soft tissue thickness at extraction and after 8 wk of socket healing. The secondary objective was to correlate the facial soft tissue changes and the underlying facial bone dimensions.

## Materials and Methods

### Study Sample

Thirty-nine patients were consecutively admitted to this prospective case series study. All patients were referred to the Department of Oral Surgery and Stomatology at the University of Bern (Switzerland) for a single-tooth replacement in the anterior maxilla from canine to canine, subsequent to an inevitable tooth extraction. Exclusion criteria were systemic diseases that could alter bone and soft tissue healing, pregnancy, and subjects younger than 18 y. The study was approved by the standing ethical committee of the state of Bern, Switzerland, and is a continuation of a previous publication (Number 079/09) (Chappuis et al. 2013). This prospective clinical trial is in accordance with the Helsinki Declaration (Version 2013) and has been registered at [www.clinicaltrials.gov](http://www.clinicaltrials.gov).

### Surgical Procedures

Prior to extraction, the patients rinsed with a 0.1% chlorhexidine solution for 1 min. Following the administration of local anesthesia, tooth extraction was performed without flap elevation using a low-trauma technique as described previously, including the placement of

a collagen sponge into the socket to stabilize the blood clot (Tissue Cone; Baxter, Chicago, IL, USA) (Chappuis et al. 2013). Medication prescribed to all subjects included analgesics and a chlorhexidine mouthwash (0.1%). A removable prosthesis was applied and adapted to avoid any direct pressure on the underlying soft tissues. Patients were recalled at 2, 4, 6, and 8 wk to monitor the healing progress, and digitized impressions were taken at each visit (Fig. 1).

### Facial Soft Tissue Thickness Immediately after Extraction and at 8 wk Postextraction

Two consecutive CBCT images were obtained, the first one immediately after extraction and the second one after 8 wk of healing. A field of view (FOV) of 4 × 4 cm with a voxel size of 0.08 mm was used to monitor dimensional alterations (3D Accuitomo XYZ Slice View Tomograph; Morita, Kyoto, Japan). To visualize the facial soft tissue thickness, a lip retractor was used during the image acquisition. The soft tissue thickness was measured 1 mm below the facial bone crest in the central site using the tooth axis as a reference at extraction and after 8 wk as described recently (Chappuis et al. 2013) (Fig. 2).

### Dimensional Facial Soft Tissue Alterations at Extraction and after 2, 4, 6, and 8 wk of Healing

The soft tissue alterations were analyzed in 5 digitized impressions taken at extraction and 2, 4, 6, and 8 wk following extraction (Fig. 1). The DICOM (Digital Imaging and Communications in Medicine) data sets were segmented by digital imaging software, and a subsequent surface mesh model was generated (Amira; FEI Visualization Sciences Group, Hillsboro, OR, USA). The surface mesh models were superimposed and rigidly aligned using anatomic landmarks by Di2Mesh software (Institute for Surgical Technology & Biomechanics, Bern, Switzerland; [www.sciencedirect.com/science/article/pii/S0079610710000726](http://www.sciencedirect.com/science/article/pii/S0079610710000726)). Distances between the surface meshes were presented as color-coded figures to identify

zones prone to dimensional soft tissue alterations and calculated as total tissue loss (Chappuis et al. 2013) (Fig. 1).

### Statistical Analysis

To test whether there was a statistical significance between 2 group medians, we used Wilcoxon signed-rank tests or Mann-Whitney *U* tests in case of unpaired comparisons. To measure correlations, the Spearman rank correlation coefficient was calculated. Nonparametric models for longitudinal data were applied to analyze the impact of bone phenotype and healing period on dimensional alterations (Brunner et al. 2002). *P* values less than 0.05 were considered significant. All statistical analyses were calculated using the open-source software R (R 3.1.0, including extension package nparLD; <http://www.r-project.org>).

## Results

### Study Sample

The population of this prospective case series study consisted of 39 patients. Six patients had to be excluded from the analysis because they revealed no facial bone wall at baseline. Fourteen women and 19 men aged between 21 and 69 y (median 47 y) were ultimately admitted to the study, which comprised 26 central incisors, 5 lateral incisors, and 2 canines. No postoperative complications were observed at the extraction sites.

### Facial Soft Tissue Thickness in Comparison with the Underlying Facial Bone Wall Anatomy

#### Facial soft tissue thickness at extraction

In thin bone phenotypes exhibiting a facial bone thickness of <1 mm (Chappuis et al. 2013), the facial soft tissue thickness and the facial bone wall thickness were in a similar range (both 0.7 mm, *P* = 0.854; Fig. 3A). In thick bone phenotypes, the soft tissue thickness (0.8 mm) was significantly thinner than the facial bone wall thickness (1.4 mm) (*P* = 0.0005; Fig. 3B). Even though a significant difference in facial bone wall thickness was observed between thin and thick bone phenotypes (median 0.7 vs. 1.4, *P* < 0.0001; Fig. 3D), there was no statistically

significant difference in facial soft tissue thickness between the phenotypes (median 0.7 vs. 0.8,  $P = 0.321$ ; Fig. 3C). No correlation was observed between facial bone and soft tissue thickness in thin and thick bone phenotypes ( $r = 0.33$  and 0.22, respectively).

#### Facial soft tissue thickness at 8 wk

In thin bone phenotypes, the facial soft tissue thickness increased significantly from 0.7 mm at extraction to 5.3 mm after 8 wk, with a median increase of 4.8 mm ( $P < 0.0001$ ; Fig. 3E). In thick bone phenotypes, the facial soft tissue thickness remained stable from 0.8 mm to 0.7 mm and did not change over time ( $P = 0.765$ ; Fig. 3F). Therefore significant spontaneous soft tissue thickening was observed only for thin bone phenotypes 8 wk following tooth extraction ( $P < 0.0001$ ; Fig. 3G). These results indicated a unique healing pattern for the soft tissues in thin bone phenotypes, which was therefore further analyzed.

#### Dimensional Soft Tissue Alterations in Comparison with the Underlying Facial Bone Wall Anatomy

##### Vertical and horizontal changes at extraction and 8 wk

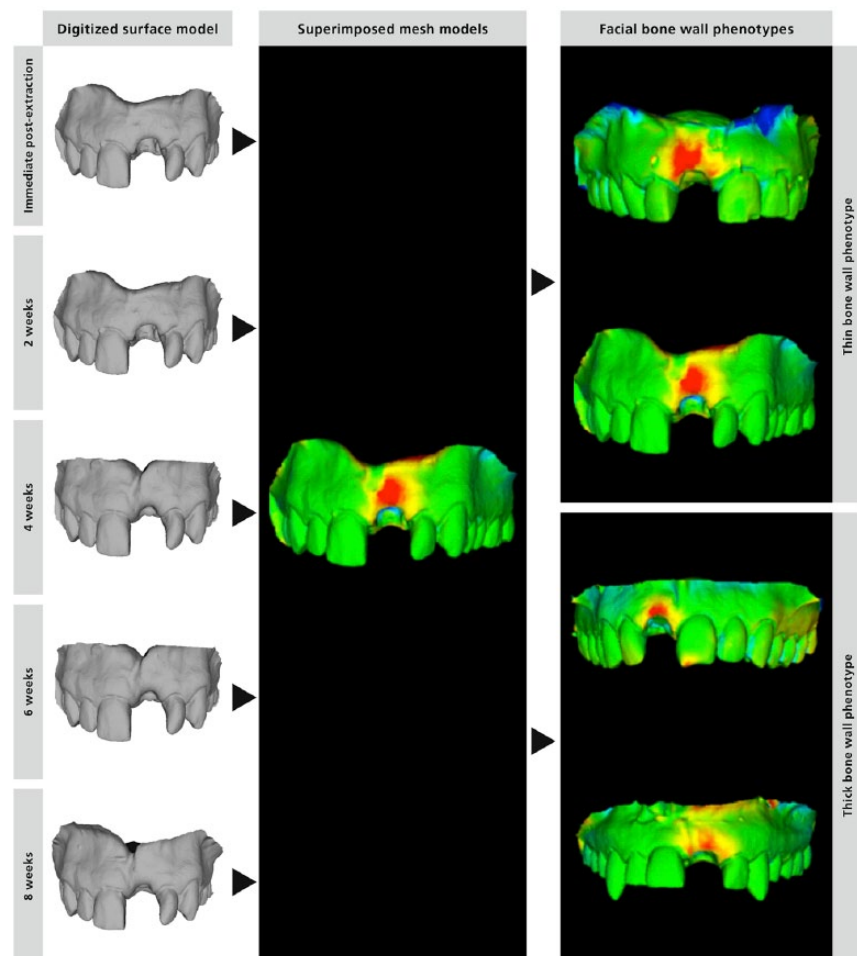
In thin bone phenotypes, the vertical tissue loss was significantly different, amounting to 7.5 mm for bone and 1.6 mm for soft tissue ( $P < 0.0001$ ; Fig. 4A), whereas in horizontal dimensions, no differences were observed (0.8 vs. 1 mm;  $P = 0.9729$ ; Fig. 4B). In thick bone phenotypes, the vertical tissue loss was similar between bone and soft tissue (1.1 vs. 1.4 mm;  $P = 0.3804$ ; Fig. 4C), whereas significant differences were observed for the horizontal tissue loss (0 vs. 1 mm;  $P = 0.0068$ ; Fig. 4D).

##### Total soft tissue changes at extraction and after 2, 4, 6, and 8 wk of healing

The total soft tissue changes were analyzed as the maximum distances between the superimposed color-coded figures. More than 51% of the total dimensional soft tissue changes occurred within 2 wk of healing, irrespective of the phenotype (Fig. 4E). Thin and thick bone phenotypes revealed no significant

#### Figure 1.

The soft tissue alterations were analyzed in 5 digitized impressions taken at extraction and 2, 4, 6, and 8 wk following extraction (left column). The data sets were segmented by digital imaging software (Amira; FEI Visualization Sciences Group, Hillsboro, OR, USA). Based on this segmentation result, surface mesh models were generated and rigidly aligned by Di2Mesh software (Institute for Surgical Technology & Biomechanics, Bern, Switzerland) using anatomic landmarks (middle column). The distances between the surface meshes were presented as color-coded figures to identify zones prone to dimensional soft tissue alterations and calculated as total tissue loss. Measurements of the facial soft tissue changes were based on digitized impressions, whereas the facial wall bone changes were based on cone beam computed tomography (CBCT) as described recently (Chappuis et al. 2013): a horizontal reference line was traced connecting the facial and palatal bone wall for standardized measurements. The tissue changes were analyzed in the central aspect of the former extraction socket, oriented at a 90° angle with the tooth axis as a reference. The point-to-point distance (total tissue loss) between the surface meshes with the respective angle to the reference line was obtained for each sample, and vertical and horizontal soft tissue and bone loss was calculated accordingly.



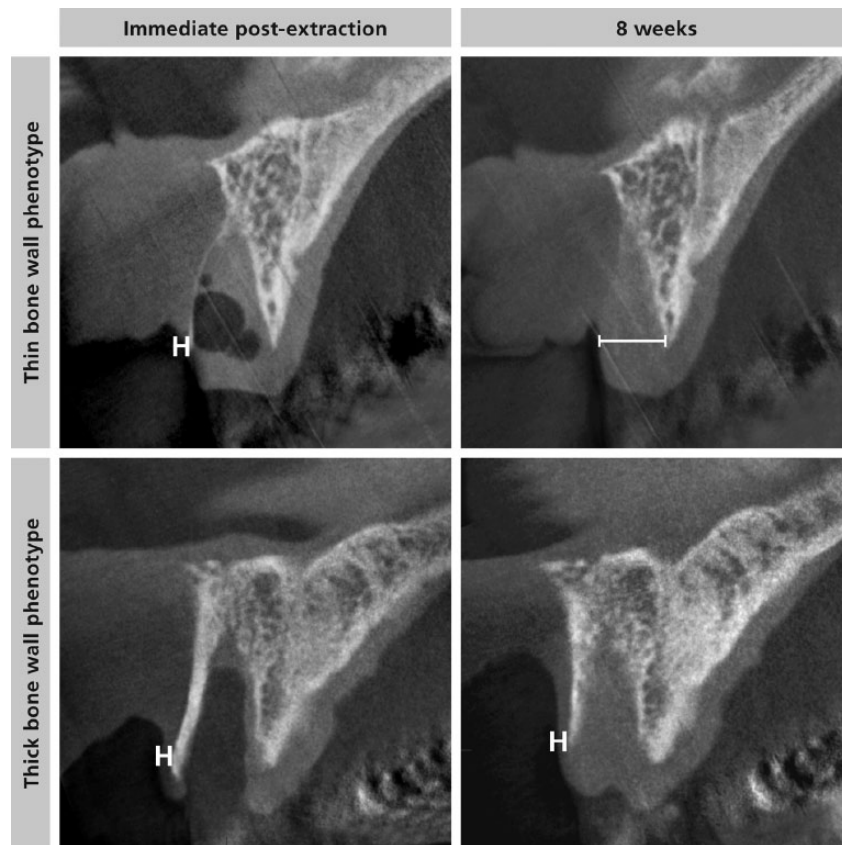
differences in the longitudinal analysis of variance (ANOVA) ( $P = 0.6$ ; Fig. 4F). However, both phenotypes showed a significant decrease over time ( $P < 0.0001$ ; Fig. 4F).

#### Discussion

The present investigation examined the interaction between dimensional alterations of the facial soft tissues and

**Figure 2.**

Measurement of the facial soft tissue thickness in thin and thick bone wall phenotypes based on the 2 cone beam computed tomography (CBCT) images at extraction and after 8 wk of healing: a horizontal reference line was traced connecting the facial and palatal bone wall for standardized measurements. Facial soft tissue thickness was measured on the facial aspect 1 mm below the reference line at extraction and after an 8-wk healing period.



the underlying facial bone wall anatomy in the esthetic zone within 8 wk of healing in postextraction sites of single teeth. At baseline, soft tissue thickness in the anterior maxilla was less than 0.8 mm, irrespective of the underlying facial bone wall anatomy. Interestingly, in thin bone phenotypes, the facial soft tissue thickness showed a 7.5-fold increase 8 wk postextraction. In addition, the dimensional alteration patterns of the facial soft and bone tissue were contradictory. Whereas the underlying facial bone wall yielded a pronounced midfacial bone loss of 7.5 mm in the vertical dimension, the soft tissue yielded a vertical reduction of only 1.6 mm. Because of this observed spontaneous soft tissue thickening in thin bone phenotypes, no significant differences in the total soft tissue contour changes

were observed between the phenotypes. Overall, more than 51% of the dimensional changes occurred early on within 2 wk of healing, irrespective of the underlying bone phenotype.

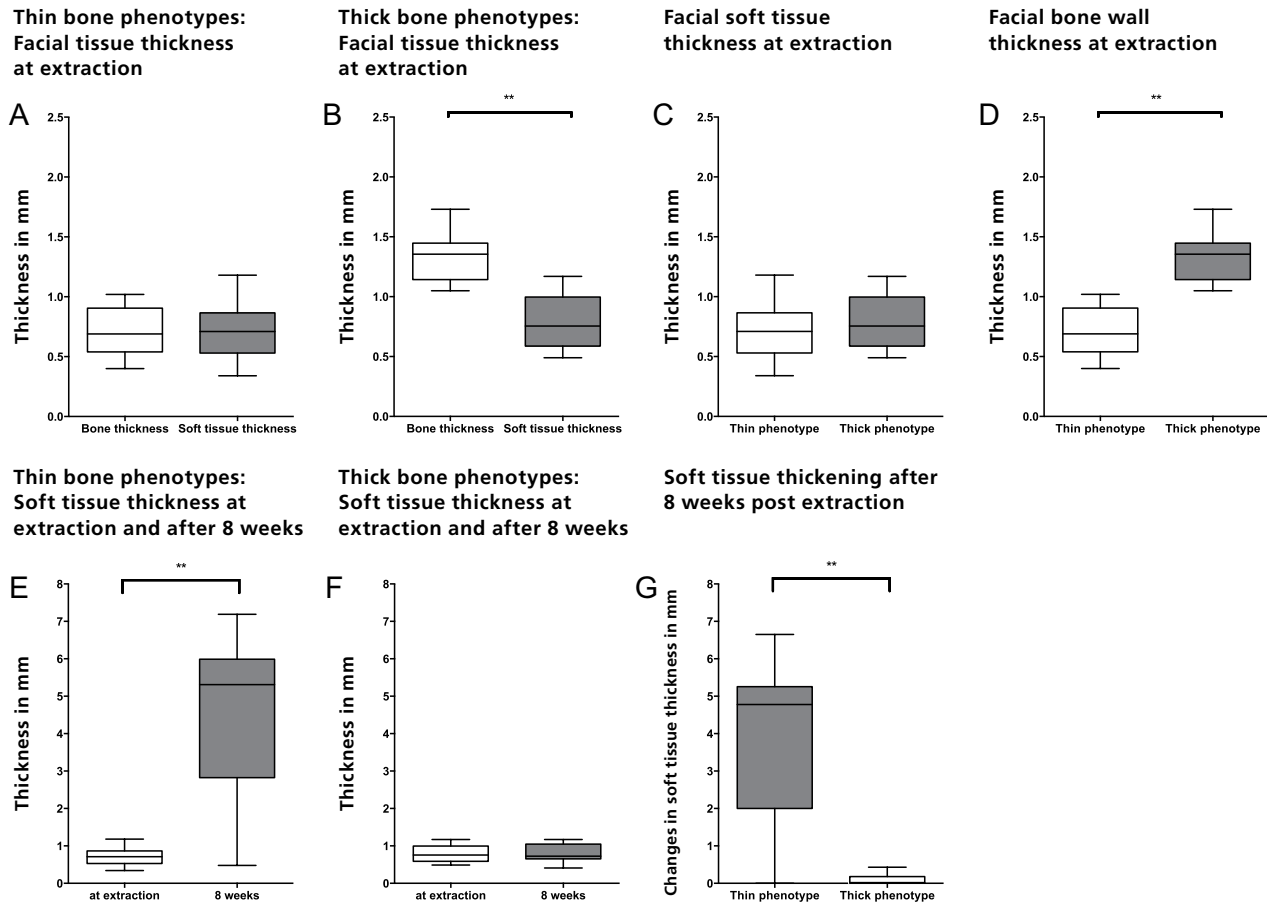
Spontaneous soft tissue thickening in thin bone phenotypes is an interesting observation. The facial soft tissue thickness in the anterior maxilla by nature is thin in most patients, ranging between 0.5 and 1 mm (Muller et al. 2000; Fu et al. 2010). Free gingival grafts and subepithelial connective grafts have been proposed as effective in increasing soft tissue volume (Thoma et al. 2014). Thicker soft tissues not only have a higher volume of extracellular matrix and collagen but also increased vascularity, which enhances clearance of toxic products and favors immune response

and growth factor migration (Hwang and Wang 2006; Nauta et al. 2011). Therefore, thicker soft tissues have been shown to respond favorably to wound healing, flap management, and restorative trauma, not only in periodontal surgery (Hwang and Wang 2006) but also in implant surgery (Evans and Chen 2008). Spontaneous soft tissue thickening in thin bone phenotypes may be a contributing factor for favorable esthetic outcomes following guided bone regeneration, as demonstrated in a 6-y prospective study (Buser et al. 2013). Therefore, spontaneous soft tissue thickening not only offers advantages for subsequent bone regeneration and implant therapies in sites with high esthetic demand but also limits the need for additional soft tissue grafting, leading to reduced morbidity and treatment costs.

The cellular and molecular mechanisms influencing this spontaneous soft tissue thickening in thin bone phenotypes are currently unknown. The current knowledge of soft tissue healing is mainly based on cutaneous wounds (Nauta et al. 2011). Mucosal wounds heal with no or only minimal scar formation and exhibit an accelerated healing pattern compared with cutaneous wounds (Szpadarska et al. 2003). Simultaneously with the formation of highly vascularized granulation tissue following tooth extraction, fibroblasts migrate into the wound (Gurtner et al. 2008). Some of these fibroblasts differentiate into myofibroblasts, which stabilize wound margins and are critical components of wound healing (Klingberg et al. 2013). It may be hypothesized that a rapidly resorbing thin facial bone wall favors facial soft tissue ingrowth because of its high proliferative rate. Thus, these soft tissue cells occupy the majority of the available space in the former extraction socket, favoring spontaneous soft tissue thickening in thin bone phenotypes. This is in contrast to thick bone phenotypes, where the alveolus provides a self-contained bony defect, which in turn favors the ingrowth of cells from the bony socket walls and the surrounding bone marrow space. In sites with minimal bone resorption on the facial aspect, soft tissue ingrowth

**Figure 3.**

Facial soft and bone tissue thickness at extraction: **(A)** In thin bone phenotypes, the facial soft tissue thickness and the facial bone wall thickness were in a similar range (both 0.7 mm,  $P = 0.854$ ). **(B)** In thick bone phenotypes, the soft tissue thickness (0.8 mm) was significantly thinner than the facial bone wall (1.4 mm) ( $P = 0.0005$ ). **(C)** The facial soft tissue thickness between thin and thick bone phenotypes yielded no difference (0.7 vs. 0.8 mm;  $P = 0.321$ ). **(D)** A significant difference was observed regarding facial bone thickness (0.7 vs. 1.4 mm;  $P < 0.0001$ ). Facial tissue soft thickness at 8 wk: **(E)** In thin bone phenotypes, the facial soft tissue thickness increased significantly from 0.7 mm at extraction to 5.3 mm at 8 wk following extraction ( $P < 0.0001$ ). **(F)** In thick bone phenotypes, the facial soft tissue thickness remained stable from 0.8 mm to 0.7 mm and did not change over time ( $P = 0.765$ ). **(G)** Significant spontaneous soft tissue thickening was observed for thin bone phenotypes 8 wk following tooth extraction, indicating a unique soft tissue healing pattern in thin bone phenotypes ( $P < 0.0001$ ). \* $P < 0.05$ . \*\* $P < 0.001$ .



will take place only superficially. On a molecular level, soft tissue thickening at 8 wk is paralleled by a peak in endothelial cell density, BMP-7, and osteocalcin expression (Trombelli et al. 2008). Therefore, the molecular and cellular mechanisms that control new bone formation may also influence soft tissue thickening (Gerstenfeld et al. 2003; Ai-Aql et al. 2008).

This hypothesis is supported by clinical studies analyzing postextraction sites and ridge preservation techniques. A trend toward soft tissue thickening following tooth extraction has also been shown by

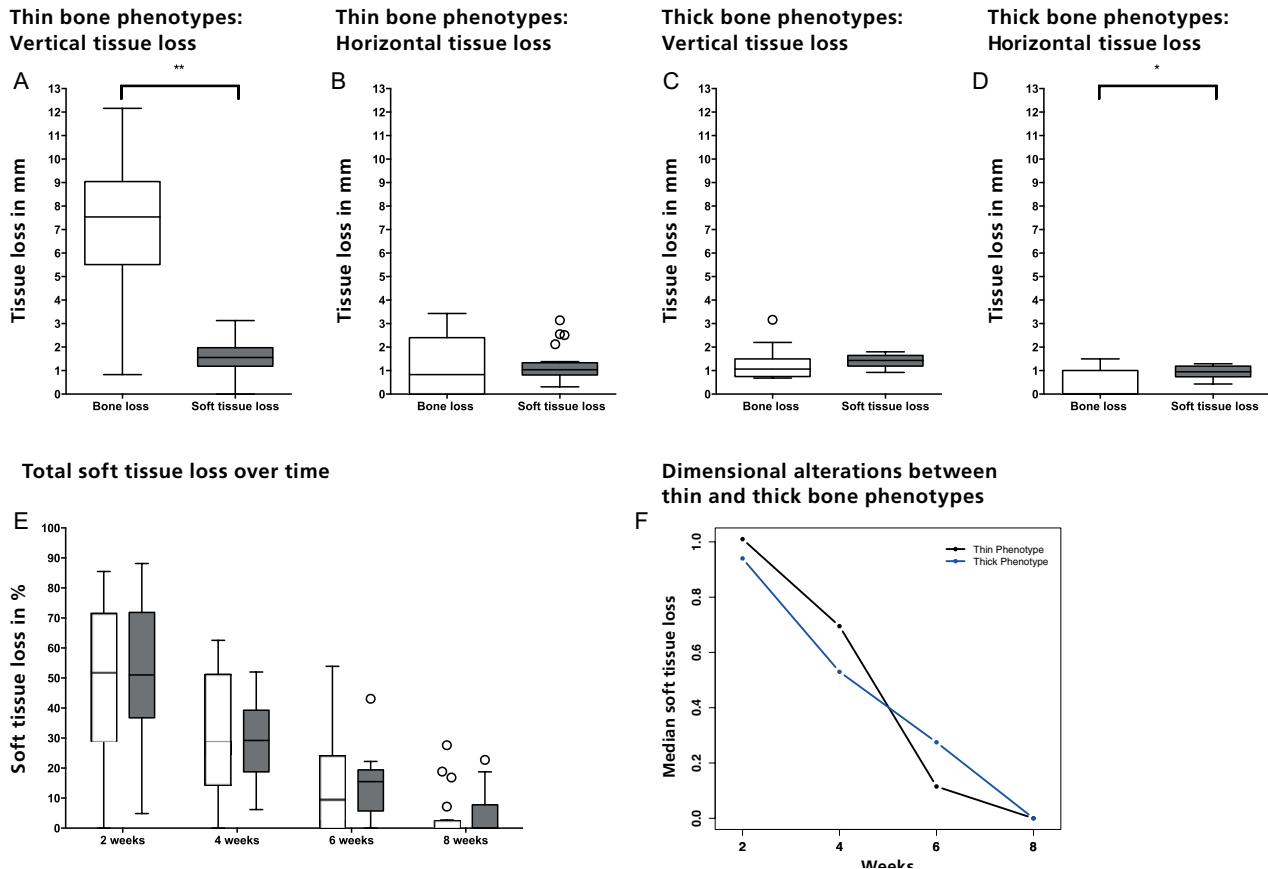
other researchers. A slight increase in soft tissue thickness, ranging from 0.09 to 0.30 mm, was observed 6 to 8 wk following single-tooth extraction in the esthetic zone (Farmer and Darby 2014). One study described postextraction sites left untreated or treated with bone substitute material and a collagen membrane (Iasella et al. 2003). At 4 and 6 mo of healing, the authors reported a significant increase in soft tissue thickness (0.4 mm) in sites left untreated compared with a significant decrease (−0.1 mm) in treated sites. In sites where a barrier membrane was placed to protect

the socket grafting material, the mucosa was thinner after healing than at baseline (Iasella et al. 2003). A recent report on ridge preservation revealed less bone loss in grafted sites compared with extraction alone (Jung et al. 2013). However, no significant soft tissue contour changes were observed (Schneider et al. 2014), which implies that there are thicker soft tissues in nongrafted sites.

Since healing of a wound such as an open extraction socket is complex and driven by sequential interplay of different tissue structures and cells types, the present study has limitations. First,

**Figure 4.**

Dimensional soft tissue alterations in comparison with the underlying facial bone wall anatomy: **(A)** In thin bone phenotypes, the vertical tissue loss was significantly different and amounted to 7.5 mm for bone and 1.6 mm for soft tissue ( $P < 0.0001$ ). **(B)** In horizontal dimensions, no differences were observed between bone and soft tissue loss (0.8 vs. 1 mm;  $P = 0.9729$ ). **(C)** In thick bone phenotypes, the vertical tissue loss was similar between bone and soft tissue (1.1 vs. 1.4 mm;  $P = 0.3804$ ). **(D)** Significant differences were observed for the horizontal tissue loss between bone and soft tissue (0 vs. 1 mm;  $P = 0.0068$ ). The total soft tissue changes were analyzed as the maximum distances between the superimposed color-coded figures at extraction and after 2, 4, 6, and 8 wk of healing: **(E)** More than 51% of the total dimensional soft tissue changes occurred within 2 wk of healing, irrespective of the phenotype. **(F)** Thin and thick bone phenotypes revealed no significant differences in the longitudinal analysis of variance ( $P = 0.6$ ). However, both phenotypes showed a significant decrease over time ( $P < 0.0001$ ). \* $P < 0.05$ . \*\* $P < 0.001$ .



since only sites in the anterior maxilla were involved, the results can only be applied to extraction sites in the esthetic zone. Second, the study was limited to an 8-wk healing period, since this is the standard healing period for early implant placement in our group. A longer healing period could potentially produce different results. Third, early immature bone formation cannot be detected early on by CBCT and may have influenced the outcomes. Finally, the study sample, which could be recruited within 2 y, is rather small, and the results have to be interpreted with care. Future studies are needed to further analyze the influence

of immediate implant placement (Araujo et al. 2005; Degidi et al. 2013; Lee et al. 2014; Favero et al. 2015) or immediate socket grafting and subsequent implant placement 6 mo later (Avila-Ortiz et al. 2014; Araujo et al. 2015) in comparison with early implant placement after 8 wk of soft tissue healing (Buser et al. 2013). All 3 approaches should be examined with each other in controlled studies concerning soft and hard tissue alterations to improve the understanding of tissue biology. Two recent CBCT short-term case series studies (Degidi et al. 2013; Lee et al. 2014) with immediate implant placement and simultaneous

buccal bone gap grafting using a low-substitution bone filler showed promising results with minimal facial bone wall alterations. Both studies used strict inclusion criteria and limited this immediate implant placement approach to patients with an intact facial bone wall postextraction. In addition, the development of new biomedical software applications to facilitate 3-dimensional tissue analysis would be desirable for implant-related research to be able to include a larger sample size, analyze different tooth positions in both arches, assess the effect of tooth tipping, and finally compare the influence of different



regenerative measures or immediate implant placement protocols.

In conclusion, in thin bone phenotypes, the facial soft tissue thickness revealed a spontaneous 7.5-fold increase and did not follow the pronounced resorption pattern of the underlying bone anatomy at 8 wk postextraction. A thorough understanding of tissue biology, including dimensional alterations of the facial soft tissues postextraction and their interaction with facial bone wall resorption, is fundamental for successful implant therapy in the esthetic zone.

### Author Contributions

V. Chappuis, O. Engel, D. Buser, contributed to conception, design, data acquisition, analysis, and interpretation, drafted and critically revised the manuscript; K. Shahim, M. Reyes, contributed to design and data acquisition, critically revised the manuscript; C. Katsaros, contributed to conception and design, critically revised the manuscript. All authors gave final approval and agree to be accountable for all aspects of the work.

### Acknowledgments

The study was supported by the ITI Foundation (Basel, Switzerland; No. 624\_2009). The authors declare no potential conflicts of interest with respect to the authorship and/or publication of this article.

### References

- Ai-Aql ZS, Alagl AS, Graves DT, Gerstenfeld LC, Einhorn TA. 2008. Molecular mechanisms controlling bone formation during fracture healing and distraction osteogenesis. *J Dent Res.* 87(2):107–118.
- Araujo MG, Lindhe J. 2005. Dimensional ridge alterations following tooth extraction: an experimental study in the dog. *J Clin Periodontol.* 32(2):212–218.
- Araujo MG, da Silva JC, de Mendonca AF, Lindhe J. 2015. Ridge alterations following grafting of fresh extraction sockets in man: a randomized clinical trial. *Clin Oral Implants Res.* 26(4):407–412.
- Araujo MG, Sukekava F, Wennstrom JL, Lindhe J. 2005. Ridge alterations following implant placement in fresh extraction sockets: an experimental study in the dog. *J Clin Periodontol.* 32(6):645–652.
- Avila-Ortiz G, Elangovan S, Kramer KW, Blanchette D, Dawson DV. 2014. Effect of alveolar ridge preservation after tooth extraction: a systematic review and meta-analysis. *J Dent Res.* 93(10):950–958.
- Belser UC, Buser D, Hess D, Schmid B, Bernard JP, Lang NP. 1998. Aesthetic implant restorations in partially edentulous patients—a critical appraisal. *Periodontol* 2000. 17(1):132–150.
- Brunner E, Domhof S, Langer F. 2002. Nonparametric analysis of longitudinal data in factorial experiments. New York (NY): John Wiley.
- Buser D, Chappuis V, Kuchler U, Bornstein MM, Wittneben JG, Buser R, Cavusoglu Y, Belser UC. 2013. Long-term stability of early implant placement with contour augmentation. *J Dent Res.* 92(12 Suppl):176S–182S.
- Cardaropoli G, Araujo M, Lindhe J. 2003. Dynamics of bone tissue formation in tooth extraction sites: an experimental study in dogs. *J Clin Periodontol.* 30(9):809–818.
- Chappuis V, Engel O, Reyes M, Shahim K, Nolte LP, Buser D. 2013. Ridge alterations post-extraction in the esthetic zone: a 3D analysis with CBCT. *J Dent Res.* 92(12 Suppl):195S–201S.
- Chen ST, Buser D. 2014. Esthetic outcomes following immediate and early implant placement in the anterior maxilla—a systematic review. *Int J Oral Maxillofac Implants.* 29(Suppl):186–215.
- DeGidi M, Dapriale G, Nardi D, Piattelli A. 2013. Buccal bone plate in immediately placed and restored implant with Bio-Oss® collagen graft: a 1-year follow-up study. *Clin Oral Implants Res.* 24(11):1201–1205.
- Evans CD, Chen ST. 2008. Esthetic outcomes of immediate implant placements. *Clin Oral Implants Res.* 19(1):73–80.
- Farmer M, Darby I. 2014. Ridge dimensional changes following single-tooth extraction in the aesthetic zone. *Clin Oral Implants Res.* 25(2):272–277.
- Favero G, Lang NP, Romanelli P, Pantani F, Caneva M, Botticelli D. 2015. A digital evaluation of alveolar ridge preservation at implants placed immediately into extraction sockets: an experimental study in the dog. *Clin Oral Implants Res.* 26(1):102–108.
- Fu JH, Yeh CY, Chan HL, Tatarakis N, Leong DJ, Wang HL. 2010. Tissue biotype and its relation to the underlying bone morphology. *J Periodontol.* 81(4):569–574.
- Gerstenfeld LC, Cullinane DM, Barnes GL, Graves DT, Einhorn TA. 2003. Fracture healing as a post-natal developmental process: molecular, spatial, and temporal aspects of its regulation. *J Cell Biochem.* 88(5):873–884.
- Gurtner GC, Werner S, Barrandon Y, Longaker MT. 2008. Wound repair and regeneration. *Nature.* 453(7193):314–321.
- Hwang D, Wang HL. 2006. Flap thickness as a predictor of root coverage: a systematic review. *J Periodontol.* 77(10):1625–1634.
- Iasella JM, Greenwell H, Miller RL, Hill M, Drisko C, Bohra AA, Scheetz JP. 2003. Ridge preservation with freeze-dried bone allograft and a collagen membrane compared to extraction alone for implant site development: a clinical and histologic study in humans. *J Periodontol.* 74(7):990–999.
- Januario AL, Duarte WR, Barriviera M, Mesti JC, Araujo MG, Lindhe J. 2011. Dimension of the facial bone wall in the anterior maxilla: a cone-beam computed tomography study. *Clin Oral Implants Res.* 22(10):1168–1171.
- Jung RE, Philipp A, Annen BM, Signorelli L, Thoma DS, Hammerle CH, Attin T, Schmidlin P. 2013. Radiographic evaluation of different techniques for ridge preservation after tooth extraction: a randomized controlled clinical trial. *J Clin Periodontol.* 40(1):90–98.
- Klingberg F, Hinz B, White ES. 2013. The myofibroblast matrix: implications for tissue repair and fibrosis. *J Pathol.* 229(2):298–309.
- Lee EA, Gonzalez-Martin O, Fiorellini J. 2014. Lingualized flapless implant placement into fresh extraction sockets preserves buccal alveolar bone: a cone beam computed tomography study. *Int J Periodontics Restorative Dent.* 34(1):61–68.
- Muller HP, Schaller N, Eger T, Heinecke A. 2000. Thickness of masticatory mucosa. *J Clin Periodontol.* 27(6):431–436.
- Nauta A, Gurtner G, Longaker MT. 2011. Wound healing and regenerative strategies. *Oral Dis.* 17(6):541–549.
- Sato H, Takeda Y. 2007. Proliferative activity, apoptosis, and histogenesis in the early stages of rat tooth extraction wound healing. *Cells Tissues Organs.* 186(2):104–111.
- Schneider D, Schmidlin PR, Philipp A, Annen BM, Ronay V, Hammerle CH, Attin T, Jung RE. 2014. Labial soft tissue volume evaluation of different techniques for ridge preservation after tooth extraction: a randomized controlled clinical trial. *J Clin Periodontol.* 41(6):612–617.
- Sculean A, Gruber R, Bosshardt DD. 2014. Soft tissue wound healing around teeth and dental implants. *J Clin Periodontol.* 41(Suppl 15):S6–S22.
- Szpaderska AM, Zuckerman JD, DiPietro LA. 2003. Differential injury responses in oral mucosal and cutaneous wounds. *J Dent Res.* 82(8):621–626.
- Thoma DS, Mühlemann S, Jung RE. 2014. Critical soft-tissue dimensions with dental implants and treatment concepts. *Periodontol* 2000. 66(1):106–118.
- Trombelli L, Farina R, Marzola A, Bozzi L, Liljenberg B, Lindhe J. 2008. Modeling and remodeling of human extraction sockets. *J Clin Periodontol.* 35(7):630–639.